

## EP CASE REPORT

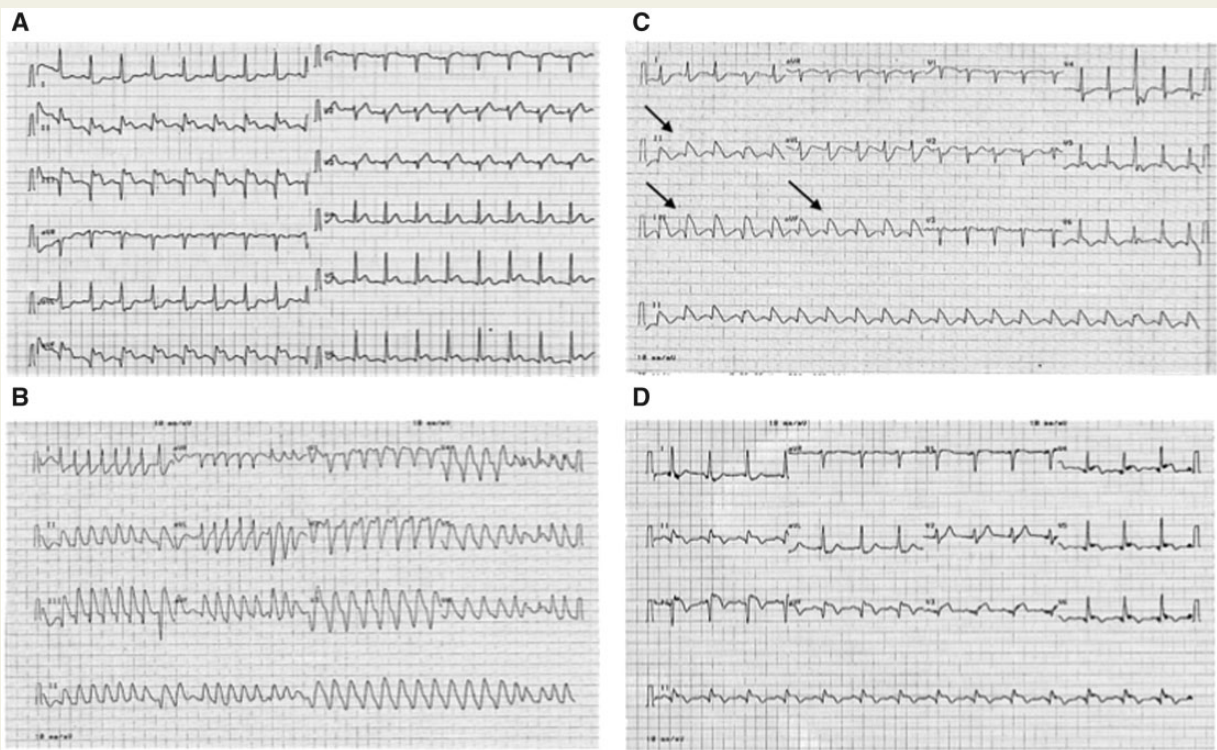
# First description of a Brugada phenocopy in the inferior leads in the context of an acute inferior myocardial infarction

Ahmet Taha Alper<sup>1</sup>, Ahmet Ilker Tekkesin<sup>1</sup>, Göksel Çinier<sup>1\*</sup>, Ceyhan Turkkan<sup>1</sup>, and Adrian Baranchuk<sup>2</sup>

<sup>1</sup>Dr. Siyami Ersek Thoracic and Cardiovascular Surgery Training and Research Center, Tibbiye Cad, 34107 Kadikoy-Istanbul, Turkey; and <sup>2</sup>Division of Cardiology, Kingston General Hospital, Queen's University, Kingston, Ontario, Canada

\* Corresponding author. Tel: +90 532 4842350; E-mail address: cinierg@gmail.com

Brugada syndrome (BrS) increases the risk of sudden cardiac death due to malignant polymorphic ventricular arrhythmias.<sup>1</sup> The diagnosis of BrS is based on typical electrocardiographic (ECG) characteristics along with symptoms and familial history. Brugada phenocopy (BrP) is a clinical entity characterized by ECG patterns that are identical to those seen in true BrS. Brugada phenocopy are associated to specific underlying clinical conditions and on the ECG normalizes upon resolution of underlying condition (i.e. electrolyte disorders). Personal or



family history of arrhythmic syncope or ventricular arrhythmias is strictly absent; and provocative tests with sodium channel blockers have to be negative.<sup>2</sup> A 67-year-old male patient with no prior medical cardiac history presented to the emergency department with anginal chest pain lasting for 1 h. His ECG revealed ST-segment elevation in leads II, III, and aVF (Figure A). A diagnosis of acute inferior myocardial infarction was made and the patient was transferred to our Cath Lab for a coronary angiography that revealed right coronary artery (RCA) occlusion in the mid segment and 50% stenosis of the circumflex artery (CX). Personal or family history of unexplained syncope, sudden cardiac death, or implantable cardiac defibrillator implantation was denied. Initial blood tests were normal except increased high sensitive troponin I: 24.98 ng/mL (0.002–0.0342). The patient presented polymorphic ventricular tachycardia (VT) with haemodynamic deterioration (Figure B). He was successfully defibrillated. Following defibrillation, the ECG revealed typical type-1 Brugada ECG morphology in leads II, III, and aVF (Figure C). Electrolytes were normal and the patient was not receiving any medication known to trigger a Brugada ECG pattern. A new coronary angiogram showed a patent stent to the RCA and no progression of the CX lesion. The ECG normalized spontaneously immediately after the angiogram (Figure D). A provocative test with ajmaline was performed 2 days later which failed to induce a type-1 Brugada ECG pattern.

Brugada phenocopies refer to certain clinical conditions presenting with an identical ECG that of true BrS but with no risk of ventricular arrhythmias. Ischaemia represents a challenge when presenting with a Brugada ECG pattern: it can be a 'modulator' of true BrS or a BrP.<sup>3</sup> In order to help differentiating both clinical conditions, a provocative test with a sodium channel blocker is useful. Even when not perfect, a negative test would indicate the presence of BrP, like in the case presented here.

The novelty of the presented case is that to the best of our knowledge, no prior case of BrP with ECG manifestations in the inferior leads has been previously reported. The mechanism remains speculative, and despite a normal angiogram after the ECG manifestation, ischaemia (either due to vasospasm or transient embolization) cannot be completely ruled out. In one study, it was demonstrated it is not infrequent that the ECG changes can occur in the context of coronary vasospasm without symptoms.<sup>4</sup>

Sarkozy *et al.*<sup>5</sup> screened 280 patients previously diagnosed with BrS for inferior-lateral repolarization abnormalities. Typical BrS ECG pattern did not occur spontaneously in any patients and did occur only 4.3% of patients in inferior-lateral leads following provocative tests. The authors recommended that patients with a typical Brugada ECG morphology in inferior leads with provocative tests should be diagnosed as BrS even without the diagnostic type I ECG criteria in right precordial leads. The exact mechanism responsible for the BrS ECG pattern in inferior-lateral leads remained to be unknown in this study.

In our patient, two distinct events were induced by possible coronary vasospasm. First, polymorphic VT was induced by ischaemia since BrP is not associated with malignant arrhythmias and second, BrP in inferior leads. Coronary spasm in RCA can be located after the RV branch which can explain the absence of ST segment elevation in right precordial leads. Spontaneous resolution of BrP and the absence of other underlying contributors to BrP support our hypothesis. Brugada syndrome is less likely in the context of lack of typical family and medical history and negative provocative test.

## References

1. Bayes de Luna A, Brugada J, Baranchuk A, Borggrefe M, Breithardt G, Goldwasser D *et al.* Current electrocardiographic criteria for diagnosis of Brugada pattern: a consensus report. *J Electrocardiol* 2012;**45**:433–42.
2. Anselm DD, Gottschalk BH, Baranchuk A. Brugada phenocopies: consideration of morphologic criteria and early findings from an international registry. *Can J Cardiol* 2014;**30**:1511–5.
3. Gottschalk BH, Anselm DD, Baranchuk A. Brugada phenocopy induced by ischemia or Brugada syndrome unmasked by ischemia? *Int J Cardiol* 2014;**177**:619–20.
4. de Luna AB, Carreras F, Cladellas M, Oca F, Sagues F, Moll MG. Holter ECG study of the electrocardiographic phenomena in Prinzmetal angina attacks with emphasis on the study of ventricular arrhythmias. *J Electrocardiol* 1985;**18**:267–75.
5. Sarkozy A, Chierchia GB, Paparella G, Boussy T, De Asmundis C, Roos M *et al.* Inferior and lateral electrocardiographic repolarization abnormalities in Brugada syndrome. *Circ Arrhythm Electrophysiol* 2009;**2**:154–61.